

# Minimally Invasive Treatment Options for Uterine Fibroids

Case Study and Commentary, Jay Goldberg, MD, MSCP, Jessica Bromberg, BS, and Swetha Srinivasan, BS



CME jointly sponsored by  
Wayne State University School of Medicine  
and JCOM

The following article, "Minimally Invasive Treatment Options for Uterine Fibroids" is a continuing medical education (CME) article. To earn credit, read the article and complete the CME evaluation on pages xxx and xxx.

## Program Audience

Primary care physicians.

## Educational Needs Addressed

Over 10,000 new cases of cervical cancer and nearly 4000 cervical cancer–related deaths occurred in the United States last year. Detection of cervical cancer in its earliest stages is lifesaving, and efforts are needed to improve low levels of compliance with screening guidelines. New technology for performing cervical cytology has evolved, as have recommendations for classifying and interpreting results. Major developments include revision of the Bethesda.

## Educational Objectives

After participating in this CME activity, primary care physicians should be able to

1. Understand the use of the Bethesda System terminology for reporting Pap test results
2. Know the recommended guidelines for timing and method of cervical cancer screening
3. Describe approaches to improving screening rates
4. Describe the management options for women with abnormal cervical cytology results

Uterine fibroids are the most common tumors of the female reproductive tract. These benign tumors occur in approximately xx% of U.S. women [can you state?], with prevalence rates of over 50% among African-American women [1]. Fibroids may vary in size, from microscopic to larger than a basketball, with many

women having multiple fibroids. Most [isn't this true?] women with fibroids are asymptomatic; these women may be diagnosed when an enlarged firm uterus is palpated on routine examination or incidentally noted on an imaging study. Symptoms caused by uterine fibroids include heavy and irregular vaginal bleeding, pelvic pain and pressure, abdominal distension, dyspareunia, and urinary frequency. Infertility and pregnancy complications are also associated with uterine fibroids. While usually not life-threatening, fibroids may have significant negative impact on a woman's quality of life [1].

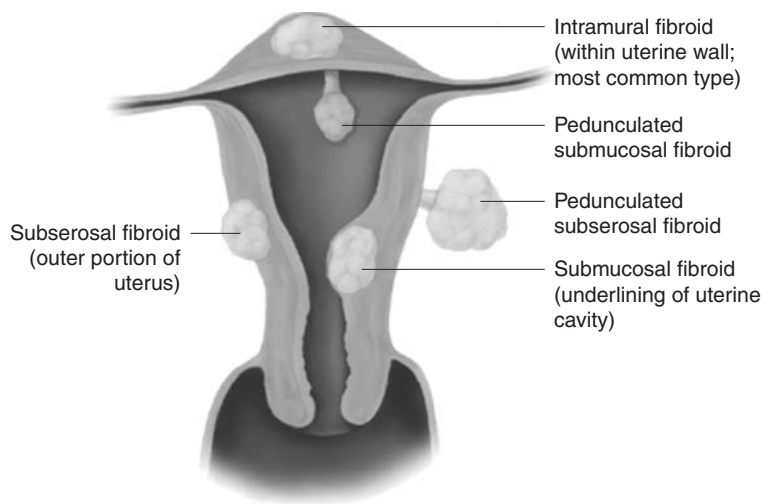
Treatment options for symptomatic fibroids range from expectant management to major surgery. Expectant management of uterine fibroids should always be offered, although its acceptability will depend on the severity of symptoms and the individual patient's tolerability threshold. This may be an especially good option in perimenopausal women, whose fibroid volume and symptoms may spontaneously decrease with the decreasing estrogen and progesterone levels of menopause.

Depending on the severity of a woman's complaints, most symptomatic women will initially attempt medical treatment. Medications most often prescribed to treat fibroids include analgesics (usually nonsteroidal anti-inflammatory drugs [NSAIDs]) and combination oral contraceptive pills. Gonadotropin-releasing hormone (GnRH) agonists have been shown to temporarily reduce fibroid volume up to 40% while also decreasing vaginal bleeding [2]. They have a significant side effect profile (including hot flashes, mood swings, and bone loss) and are costly, and fibroids rapidly return to baseline size and symptomatology once therapy is discontinued; therefore, GnRH agonists are useful in select situations, such as to temporarily shrink the fibroid or to increase a patient's low red blood cell [correct?] count prior to surgery [1].

Hysterectomy or myomectomy have been the most common treatments for women with symptomatic uterine fibroids refractory to medical management. In the United States, approximately 250,000 women undergo hysterectomy

*From the Department of Obstetrics and Gynecology, Jefferson Medical College, Philadelphia, PA.*

## UTERINE FIBROIDS




**Figure.** Fibroids classified by location. (Reprinted with permission from BioSphere Medical.)

annually for symptomatic fibroids, with approximately 35,000 undergoing myomectomy [3]. Hysterectomy, a definitive treatment, is the only treatment that can guarantee resolution of both bleeding and bulk symptoms. While myomectomy preserves the uterus, up to 25% of women undergoing myomectomy will eventually require additional procedures for recurrent symptoms due to persistent symptoms or growth of new fibroids [4]. Both hysterectomy and myomectomy, most commonly performed via laparotomy, involve a 4- to 6-week recovery period. Complications may occur in up to one third of procedures and may include infection, bleeding, and damage to internal structures; most frequently, however, the complications are minor [5]. An increasing number of women, including those not desiring future fertility and especially African-American patients, are declining hysterectomy as an option due to cultural and body image issues [6]. Laparoscopic hysterectomy and laparoscopic myomectomy may be appropriate in select patients and may allow a shorter convalescence [ok as edited?].

A number of minimally invasive, alternative treatments for symptomatic fibroids are available to women. These include uterine artery embolization (UAE), magnetic resonance imaging (MRI)-guided focused ultrasound therapy, laparoscopic uterine artery occlusion/coagulation, endometrial ablation, and the levonorgestrel-releasing intrauterine device (LNG-IUD). This case-based review will discuss these options, with a focus on UAE.

### CASE STUDY

#### Initial Presentation

 A 40-year-old woman presents to her gynecologist complaining of increasingly heavy and painful menses and pelvic pressure.

#### History

Over the past 9 months, the patient's periods have become significantly heavier, with more painful cramps, for which she has self-treated with NSAIDs. Additionally, she complains of an increasingly occurring sensation of low pelvic pressure, which becomes worse with activity. Over this time period, she has had to void more frequently, including 3 to 4 episodes of nocturia per night. The patient also reports feeling weak and fatigued. She denies any other symptoms, including intermenstrual bleeding, dysuria, or dyspareunia.

She reports a history of a single small uterine fibroid, previously documented on examination and by pelvic ultrasound. Otherwise, she has no significant past medical history. Her past surgical history includes a laparoscopic tubal ligation and cesarean section. She has had 2 spontaneous vaginal deliveries and no sexually transmitted diseases or previous menstrual disorders. Her last routine gynecologic examination was 2 years ago.

- 
- **What is the approach to evaluation in a patient with suspected symptomatic uterine fibroids?**
- 

The diagnosis of uterine fibroids (**Figure**) involves a combination of patient history, physical examination, radiologic imaging, and laboratory testing. Initially, it is most important to rule out malignancy. Although a rapid increase in the size of the uterus raises suspicion for uterine leiomyosarcoma, its incidence is extremely rare, especially in a premenopausal woman. Parker et al [7] found only a 0.27% incidence in 371 women undergoing hysterectomy for suspected leiomyosarcoma.

#### Physical Examination

 On physical examination, the patient is healthy in

appearance. Her vital signs are within normal limits. The abdominal examination reveals no tenderness, but there is a palpable pelvic mass. Speculum examination demonstrates a normal-appearing cervix, with no visible lesions. On bimanual examination, the physician palpates an enlarged and firm uterus estimated to be 14 gestational weeks' size thought to represent an enlarged fibroid uterus. Her adnexa are not palpable.


### Laboratory Testing and Imaging

Given her symptoms of heavy menstrual bleeding and fatigue, a hemoglobin is ordered to screen for anemia, confirmed by a value of 9.0 g/dL. An endometrial biopsy is performed in the office to rule out endometrial hyperplasia or cancer, with benign pathologic findings. A urine culture, ordered due to the complaints of urinary frequency, is negative. An MRI is ordered to verify that the pelvic mass represents a fibroid uterus rather than an ovarian process and to better describe the number, size, and location of the fibroids. The MRI findings are consistent with the physical examination, revealing an enlarged, irregular uterus measuring 14 × 10 × 10 cm with multiple intramural fibroids up to 5 cm in diameter. The endometrial lining was distorted and could not be measured. Both ovaries were visualized and appear normal.

- 
- What are the treatment goals for patients with uterine fibroids?
- 

The primary goal for most patients with patients with fibroids is alleviating bleeding and bulk symptoms, thus improving their quality of life. In patients who desire future fertility, goals may also include improving pregnancy rates while decreasing risk for fibroid-associated spontaneous abortion or pregnancy complications.

### Follow-up

 After obtaining results from the endometrial biopsy, urine culture, and pelvic MRI, the patient returns to the office for a discussion of treatment options for her symptomatic uterine fibroids. The patient reported a significant impact on her quality of life resulting from the fibroids. Having previously undergone sterilization, she did not desire future fertility. NSAIDs have been ineffective. Given her complaints of significant bulk as well as bleeding symptoms, oral contraceptive pills were not recommended as a good option. As she was approximately 10 years prior to the expected onset of menopause, the use of a GnRH agonist would have only provided temporary relief with significant side effects. Hysterectomy and myomectomy were offered; however, due to their time to recovery,

the risks of major surgery, and the patient's desire for uterine preservation, they were not acceptable to her.

- 
- What minimally invasive treatment options are available for uterine fibroids?
- 

Minimally invasive, clinically available treatment options include UAE, MRI-guided focused ultrasound therapy, laparoscopic uterine artery occlusion/coagulation, endometrial ablation, and the LNG-IUD.

### Uterine Artery Embolization

UAE has emerged over the last decade as a popular and effective nonsurgical alternative treatment for symptomatic uterine fibroids. UAE has been performed by interventional radiologists for over 2 decades in the treatment of pelvic hemorrhage following delivery or abortion, cervical or ectopic pregnancy, gestational trophoblastic disease, and pelvic malignancy [8,9]. Embolization of the uterine arteries was first reported as an effective primary treatment for symptomatic fibroids in 1995, when Jacques Ravina, a French gynecologist, noted that several women with symptomatic fibroids undergoing UAE as a premyomectomy treatment to potentially decrease surgical risk had such significant clinical improvement that myomectomy was no longer necessary [10].

### Embolization Technique

UAE is a procedure performed by interventional radiologists using either local or regional anesthesia. An arteriogram is performed to visualize the pelvic vasculature. Fluoroscopic guidance enables a catheter to be passed into the right femoral artery through the right external iliac artery to the aorta, then down the left common iliac artery to the left internal iliac, down the anterior division, and finally to the left uterine artery. Most commonly, acrylic copolymer beads (500–700 μm) or polyvinyl alcohol particles are then infused until slow flow or stasis occurs in the uterine artery and the fibroid vasculature is occluded. The catheter is then pulled back and manipulated down into the right uterine artery, which is similarly embolized. Procedure time ranges from 15 to 120 minutes depending on the patient's anatomy and skill of the interventional radiologist. UAE may be either an outpatient procedure or require an overnight hospitalization, mainly for pain relief. Patients typically return to work within 7 to 10 days [1,3,11–13].

### Outcomes

In the worldwide UAE experience, which now approaches 100,000 cases, this procedure has been shown to be an effective and safe treatment for symptomatic uterine fibroids [1].

Spies et al [12] prospectively studied 200 consecutive women undergoing uterine fibroid embolization. He reported improvement in heavy bleeding in 90% (95% confidence interval [CI], 86%–95%) and bulk symptoms in 91% (95% CI, 86%–95%) at 1 year. Eleven percent of the patients (95% CI, 7%–15%) underwent subsequent gynecologic intervention during the 12-month follow-up period [12]. Similarly, the Ontario Uterine Fibroid Embolization Trial [14], a prospective, multicenter study, observed reductions in the median uterine and dominant fibroid volume of 35% and 42%, respectively, following UAE. Of 583 patients, 91% expressed satisfaction with their procedure, including significant improvement for menorrhagia (83%), dysmenorrhea (77%), and urinary complaints (86%) [14]. Another multicenter prospective cohort study evaluated women undergoing UAE ( $n = 102$ ) and hysterectomy ( $n = 50$ ) for symptomatic fibroids [5]. The mean uterine volume was 1.8 times greater for patients undergoing UAE. There was significant improvement in symptoms and quality of life scores in both groups. Overall morbidity occurred more frequently in women in the hysterectomy group compared with the UAE group (34% versus 14.7%;  $P = 0.01$ ). Most complications in both groups were minor [5]. Data are also recently available on long-term outcomes from UAE. Spies et al [15] published a series of 200 consecutive patients followed after UAE for 5 years. At the end of 5 years, 73% reported continued symptom relief, 18% had undergone hysterectomy or myomectomy, and 2% had a repeat UAE. Long-term failure was greatest for women with larger baseline fibroid volumes and those not improved at 1 year [15].

Patients often report some degree of a “postembolization syndrome,” which clinically presents with low-grade fever, pain, malaise, nausea, and leukocytosis, generally within the first 4 days post-UAE [9]. This may be caused by the systemic effects of transient ischemia to the fibroids and uterus in general. While usually self-limiting and treatable with antipyretics and analgesics on an outpatient basis, these patients are often admitted for observation and antibiotic therapy. While rare, ovarian failure, transcervical passage of submucosal fibroids, and death have been reported following UAE. In a recent analysis of the procedure [16], major complications occurred in approximately 0.5% of UAE performed for symptomatic fibroids.

### Indications/Contraindications

Indications for UAE, as for hysterectomy and myomectomy, are symptomatic uterine fibroids refractory or unamenable to medical management. In addition, UAE may be an especially useful option for women who are poor surgical candidates, with extensive adhesive disease, who refuse blood products, who are perimenopausal or who prefer to avoid surgery [1]. Patients are required to have an MRI prior to

having the UAE procedure done [**required by authorities or just standard practice**]. For this reason, this patient’s physician earlier ordered an MRI (rather than a pelvic ultrasound) to enable the patient to choose UAE as a treatment option. [**OK here and as edited?**]

Pelvic infection, severe contrast allergy, arteriovenous shunting, the presence of an undiagnosed pelvic mass, coagulopathy, renal insufficiency, history of pelvic radiation, and genital tract malignancy are all contraindications for UAE. Desire for future fertility is currently considered a relative contraindication to UAE by the American College of Obstetricians and Gynecologists [17]. Previous publications by Goldberg and colleagues [11,18] reported increased pregnancy complications following UAE, including higher rates of premature delivery, compared to the general population and patients with prior myomectomies. In agreement with Goldberg’s findings, a recent Canadian study did report that most pregnancies conceived following UAE, while having slightly increased rates of premature delivery, still had good outcomes [19].

### Levonorgestrel-releasing Intrauterine Device

The LNG-IUD has been shown to be an effective treatment for menorrhagia, an effect thought to be largely due to progestin-induced endometrial atrophy [20]. The use of LNG-IUD in women with fibroids has been associated with a decrease in fibroid volume, a lower rate of new fibroid development, and a decrease in the need for hysterectomy [21,22].

A Turkish study favorably compared LNG-IUD treatment for fibroid-related menorrhagia ( $n = 32$ ) to historical controls that underwent thermal balloon ablation. It excluded individual submucosal fibroids larger than 3 cm or other fibroids 5 cm or larger. In women with fibroid-related menorrhagia, LNG-IUD treatment reduced pictorial blood loss-assessment chart (PBLAC) scores from  $392 \pm 41$  to  $37 \pm 19$  at 12 months, while increasing mean hemoglobin values by  $2.6 \pm 0.9$  g/dL. Seventy-eight percent of patients were overall satisfied with the effectiveness of the LNG-IUD in treating their fibroid-related menorrhagia [23].

A Brazilian study reported on 10 women receiving an for fibroid-related menorrhagia. One patient withdrew from the study after 15 days, and 2 others spontaneously expelled their IUDs. Of the remaining 7 patients, all had decreased bleeding, with 4 becoming amenorrheic. 6 patients with pre-LNG-IUD anemia normalized their hemoglobin and hematocrit values. Uterine volume ( $\text{cm}^3$ ) decreased from  $203 \pm 28$  to  $187 \pm 44$ , but there was insufficient power to attain statistical significance [24].

While these small studies show a potential role for the LNG-IUD in treating fibroid-related menorrhagia, larger studies must be reported, including the assessment of its ef-

fect on larger fibroid volumes, before the proper role of this treatment can be established.

The LNG-IUD is not recommended for patients currently desiring fertility and will not effectively treat significant fibroid bulk symptoms. While the LNG-IUD may often be an effective treatment for fibroid-associated abnormal uterine bleeding, a major limiting factor in its utilization is insurance coverage. While universally covering fibroid-associated hysterectomy, myomectomy, endometrial ablation, or UAE, less than 50% of insurers currently cover the cost of an IUD. The current out of pocket cost to a patient in our office for the LNG-IUD and its insertion is over \$700. Additionally, removal or changing of the device is recommended every 5 years. As physicians, patients, and insurers become more familiar with the benefits to women with fibroid-associated bleeding, including lowering the need for surgical treatment, insurance coverage and utilization of the LNG-IUD will possibly increase.

### Endometrial Ablation

Endometrial ablation is primarily performed in patients without uterine fibroids. Most second-generation endometrial ablation devices in U.S. Food and Drug Administration (FDA) trials excluded patients with submucosal fibroids or others larger than 2 to 4 cm. A few studies have examined endometrial ablation in patients with fibroids.

Soysal et al [25] prospectively randomized 96 women with fibroid-associated menorrhagia to rollerball ablation (RBA) and thermal balloon ablation. Patients with submucosal fibroids greater than 3 cm or uterine volume more than 12 gestational weeks were excluded. Both groups had approximately 89% decrease in mean PBLAC scores and approximately 30% increase in hemoglobin values [25].

Glasser and Zimmerman [26] reported on a subgroup of 22 patients with menorrhagia and submucosal fibroids less than 4 cm treated with the Hydrothermablator system, using circulating heated (90°C) saline in the uterus for 10 minutes. One year following treatment, 12 of 22 patients were amenorrheic, while only 2 were considered treatment failures. The overall success rate, which was defined as not requiring additional treatment, was 91% [26].

Sabbah [27] analyzed a subgroup of 24 patients treated with the NovaSure system who had submucosal fibroids measuring 1 to 3 cm. Bleeding was improved in 89%, with 67% amenorrheic. Two patients were considered treatment failures [27].

Anderson et al [28] reported on a subgroup of 71 women with menorrhagia with fibroids not exceeding 3 cm or distorting the endometrial cavity that were randomized to RBA or microwave endometrial ablation (MEA). Success rates in patients treated with MEA were 91% in patients without and 68% in patients with fibroids. Success rates in patients treated

with RBA were 86% in patients without and 77% in patients with fibroids. Rates of amenorrhea in patients treated with MEA were 61% for both patients with and without fibroids. Amenorrhea rates following RBA were 56% and 39% in patients without and with fibroids. Given limited sample size, these differences were not statistically significant [28].

Delayed fibroid degeneration has been described following MEA. Fibroid degeneration may be caused by an interruption of its blood supply, causing ischemia. The thermal effects of the endometrial ablation procedure is thought to compromise the vascular web surrounding fibroids, ultimately leading to its delayed degenerative changes, manifested as peritonitis [29].

### Uterine Artery Ligation/Coagulation/Occlusion

The uterine arteries supply the majority of blood supply to the uterus. Uterine artery ligation has been used to stop uterine hemorrhage, both in obstetric and gynecologic settings. Anecdotally, following uterine artery ligation, fibroids have been noted to decrease in size. The reason this occurs without harming the uterus is theorized to be due to the extensive collateral uterine circulation not similarly supplying fibroids, which infarct and shrink in size. Based on similar theory, a laparoscopic approach to uterine artery ligation or occlusion has been described as a primary treatment for symptomatic fibroids. Additionally, the use of energy to perform a laparoscopic uterine artery coagulation has been reported as a primary fibroid treatment. Laparoscopically, uterine arteries are identified and manipulated to allow application of vascular clips or coagulation in an area away from the ureter, reducing uterine blood supply [30].

Lee et al [30] showed a mean difference in myoma Doppler blood flow from 24.92 cm/s prelaparoscopic uterine artery occlusion to 11.63 cm/s at 4 months after laparoscopy. The study also recorded that 13 out of 14 subjects reported complete improvement in pain and pressure symptoms and 1 reported significant relief [30].

Another study by Hald et al [31] compared uterine artery occlusion with UAE. Using PBLAC score to quantify the amount of blood lost before and after the procedure, this study reported that the women who underwent UAE had a 67% reduction in mean blood loss at 6 months, while those who underwent laparoscopic uterine artery occlusion had a mean blood loss reduction of 50%. Both procedures had a 36% volume reduction in the dominant fibroid size. Women in the UAE group required more pain medications ( $P = 0.008$ ) than women in the occlusion group [31].

A study by Chen et al [32] reported a pregnancy rate of 42% with a term pregnancy rate of 6% in women who underwent laparoscopic uterine artery coagulation. The authors of this study caution that uterine artery ligation or coagulation should only be used in women who do not

desire future pregnancy due to concerns regarding changes in uterine or endometrial perfusion [32].

A study from the Czech Republic evaluated the frequency and severity of complications as well as fibroid recurrence in women with symptomatic fibroids ( $n = 114$ ) who were treated with laparoscopic occlusion of the uterine artery (LOUA). There was a minimum of 3 months' follow-up. Eight women (7.1% [95% CI, 3.3%–14.4%]) experienced complications; 1 of these women had 2 complications, resulting in a total of 8 adverse events. There were no intraoperative complications and no permanent injuries. Two women required supracervical hysterectomy and myomectomy, respectively, as a result of fibroid necrosis. One patient had an undiagnosed endometrial stromal sarcoma after 12 months of LOUA. The rate of fibroid recurrence was 9% (10 patients). The recurrence-free survival interval rate (no clinical failure, no recurrence) at 23.6 months (median) follow-up was 88.3% (95% CI, 84.9%–93.5%) [33].

Laparoscopic uterine artery occlusion/coagulation is currently only performed by a few highly skilled gynecologic laparoscopists. In inexperienced hands, there is significant potential for ureteral or vascular injury. Additional studies must be performed evaluating long-term patient outcomes and complication rates before it can be considered part of the routine spectrum of fibroid treatments.

### MRI-Guided Focused Ultrasound Therapy

On 22 October 2004, the FDA approved the first noninvasive therapy for symptomatic uterine fibroids, the ExAblate® 2000 system (InSightec, Dallas, TX), an MRI-guided focused ultrasound therapy. Patients must have a uterus less than 24 weeks' size and not desire future fertility. A required 3-year postmarket study is currently being conducted by the manufacturer to evaluate long-term effectiveness and safety of this treatment [34].

For over 50 years, the use of focused ultrasound as a thermoablative technique has been studied and clinically applied. Magnetic resonance-guided focused ultrasound surgery (MRgFUS) or high intensity-frequency ultrasound therapy is a noninvasive technique with effectiveness in localizing and targeting prostate, liver, and benign breast tumors. Most recently, this technology has been applied to treat symptomatic uterine fibroids [35–37].

MRgFUS provides real-time images of treatment areas, providing precise and multiplanar views of the tissue to be ablated. Once localized, these focal areas of fibroids are penetrated with converging high-frequency, high-energy, sound waves that cause localized high temperatures (55°C–90°C) for a few seconds. These precise areas then undergo protein denaturation, irreversible cell damage, and coagulative necrosis. Structures surrounding the fibroid are continuously imaged, and tissue responses to the thermal

energy at every treatment point are constantly monitored. Optimally, adjacent tissue is spared from a bystander effect, while temperature feedback enables the efficacy of heat waves delivery only to the targeted fibroid [38].

Two papers reported on a group of 109 MRgFUS-treated premenopausal women with symptomatic fibroids followed for 12 months [39,40]. This was the pivotal study prior to obtaining FDA approval. The mean time the patients were in the MR scanner was 202 minutes (range, 90–370 min). Only 10% of the total fibroid volume was treated due to treatment guidelines, a mean of  $1.3 \pm 0.6$  fibroids per patient. The mean time until return to work was only 1 day. Mean fibroid volume reduction was only 13.5%. Of the 109 subjects who participated in the study, 71% met the targeted treatment goal of a 10-point decrease on the Symptom Severity Scale at 6 months. Seventy-nine percent achieved at least a 10-point decrease in the Uterine Fibroid Symptoms and Quality of Life Questionnaire score ( $P < 0.001$ ). No deaths, life-threatening events, second treatments, or thromboembolic events occurred over the 6-month period. Minor complications from MRgFUS noted in the study were febrile episodes, transfusions, rehospitalization, and burns and ulcerations of the skin. Serious complications included a sciatic nerve palsy in 1 subject. At the 12-months post-MRgFUS, 23 of the 82 evaluative patients (28%) had undergone additional intervention (hysterectomy, myomectomy, UAE) for persistent symptoms. By 24 months, 40 evaluative patients of the original 109 (37%) had required additional intervention. Of 19 patients with imaging at 24 months, the volume reduction of the treated fibroid was only 4.3%.


A Blue Cross/Blue Shield Technology Evaluation Center criteria analysis of MRgFUS concluded that the available evidence on MRgFUS was not sufficient to demonstrate improvement in health outcomes and did not meet the Technology Evaluation Center criteria. It discussed that patient satisfaction and overall treatment effect are greater with other therapies for uterine fibroids: hysterectomy (95%), myomectomy (80%–90%), and UAE (90%). It also questioned the clinical value of the primary outcome for the pivotal study (10-point reduction in Symptom Severity Scale). If the threshold were raised to a 20-point improvement, success would have occurred in only 54% and 32% of MRgFUS treated patients at 6 and 12 months, respectively [34].

Although recently FDA approved, MRgFUS for symptomatic uterine fibroids is currently not covered by the majority of insurers due to questions regarding its durability and clinical benefit. As MRgFUS technology improves, its benefit of being an extracorporeal treatment with a promising safety profile may allow it to play a more prominent role in treating symptomatic fibroids.

Additional minimally invasive fibroid treatments, including myolysis, cryomyolysis, coagulation, sclerosis, and

transvaginal uterine artery occlusion, have been proposed as options for some patients [35,41–43]. Outside of the research setting, however, the efficacy, safety profiles, and cost of these treatments have limited their clinical use.

**Treatment and Follow-up**

 After discussing with her gynecologist the risks and benefits of the available minimally invasive treatments for her symptomatic fibroids, the patient elects to undergo UAE. Her decision is based on her desire for a quick recovery and uterine preservation, the most extensive reported clinical experience of all minimally invasive treatments, its safety profile, and reported clinical efficacy in treating both bleeding and bulk symptoms.

The UAE is performed on an outpatient basis by an interventional radiologist. Other than minor cramping, the patient had minimal UAE-related symptoms and experienced no complications. She was able to return to work full-time in 1 week. An MRI obtained 3 months post-UAE demonstrates a 35% reduction in uterine volume. More importantly, the patient reported having regular light menses, with significantly reduced cramping. Her bulk symptoms of pelvic pressure and urinary frequency had similarly improved.

**CONCLUSION**

Uterine fibroids are a significant health issue, negatively affecting a woman’s quality of life through bulk and bleeding symptoms. Treatment options range from expectant management to alternative minimally invasive therapies to major surgery. Of alternative minimally invasive fibroid treatments, endometrial ablation, the LNG-IUD, and UAE are the best options clinically available for patients with primarily bleeding symptoms, while UAE is the best option for patients with both bleeding and bulk symptoms. All appropriate fibroid treatment options should be discussed with patients. Factors that may play a role in the woman’s decision include treatment efficacy for bleeding and bulk symptoms, safety profile, recovery time, uterine preservation, insurance coverage, and clinical experience of the individual therapy.

*Corresponding author: Jay Goldberg, MD, MSCP, Dir., Jefferson Fibroid Ctr., Jefferson Medical College, 834 Chestnut St., Ste. 400, Philadelphia, PA 19107, jaygoldbergmd@yahoo.com.*

*Financial disclosure: Dr. Goldberg serves as a consultant for Biosphere Medical.*

*Author contributions: to come*

**References**

1. Goldberg J. Uterine fibroid embolization: a new treatment for uterine fibroids. *Female Patient* 2006;31:45–50.

2. Friedman AJ, Hoffman DI, Comite F, et al. Treatment of leiomyomata uteri with leuprolide acetate depot: a double-blind, placebo-controlled, multicenter study. *The Leuprolide Study Group. Obstet Gynecol* 1991;77:720–5.

3. Floridon C, Lund N, Thomsen SG. Alternative treatment for symptomatic fibroids. *Curr Opin Obstet Gynecol* 2001;13:491–5.

4. Stenchever MA, Droegmueller W, Herbst AL, Mishell DR, editors. *Comprehensive gynecology*. 4th ed. St. Louis (MO): Mosby; 2001:503.

5. Spies JB, Cooper JM, Worthington-Kirsch R, et al. Outcome of uterine embolization and hysterectomy for leiomyomas: results of a multicenter study. *Am J Obstet Gynecol* 2004;191:22–31.

6. Shelton AJ, Lees E, Groff JY. Hysterectomy: beliefs and attitudes expressed by African-American women. *Ethn Dis* 2001;11:732–40.

7. Parker WH, Fu YS, Berek JS. Uterine sarcoma in patients operated on for presumed leiomyoma and rapidly growing leiomyoma. *Obstet Gynecol* 1994;83:414–8.

8. Goodwin SC, Walker WJ. Uterine artery embolization for the treatment of uterine fibroids. *Curr Opin Obstet Gynecol* 1998;10:315–20.

9. Schwartz ML, Klein A, McLucas B. Using uterine artery embolization to treat uterine fibroids. *Contemp Ob Gyn* 2001;46:14–37.

10. Ravina J, Herbreteau D, Ciraru-Vigneron N, et al. Arterial embolisation to treat uterine myomata. *Lancet* 1995;346:671–2.

11. Goldberg J, Pereira L, Mude-Nochumson H. Uterine artery embolization for symptomatic fibroids: pros and cons. Available at [www.obgmanagement.com/article\\_pages.asp?AID=3092&UID=](http://www.obgmanagement.com/article_pages.asp?AID=3092&UID=). Accessed 11 Aug 2006.

12. Spies JB, Ascher SA, Roth AR, et al. Uterine artery embolization for leiomyomata. *Obstet Gynecol* 2001;98:29–34.

13. Demello AB. Uterine artery embolization. *AORN J* 2001;73:790–2, 794–8, 800–4, 809–14.

14. Pron G, Bennett J, Common A, et al. The Ontario Uterine Fibroid Embolization Trial. Part 2. Uterine fibroid reduction and symptom relief after uterine artery embolization for fibroids. *Ontario Uterine Fibroid Embolization Collaboration Group. Fertil Steril* 2003;79:120–7.

15. Spies JB, Bruno J, Czeyda-Pommersheim F, et al. Long-term outcome of uterine artery embolization of leiomyomata. *Obstet Gynecol* 2005;106(5 Pt 1):933–9.

16. Spies JB, Spector A, Roth AR, et al. Complications after uterine artery embolization for leiomyomas. *Obstet Gynecol* 2002;100(5 Pt 1):873–80.

17. ACOG Committee Opinion. Uterine artery embolization. *Committee on Gynecologic Practice, American College of Obstetricians and Gynecologists. Obstet Gynecol* 2004;103:403–4.

18. Goldberg J, Pereira L, Berghella V, et al. Pregnancy outcomes after treatment for fibromyomata: uterine artery embolization versus laparoscopic myomectomy. *Am J Obstet Gynecol* 2004;191:18–21.

19. Pron G, Mocarski E, Bennett J, et al. Pregnancy after uterine artery embolization for leiomyomata: the Ontario multi-

- center trial. Ontario UFE Collaborative Group. *Obstet Gynecol* 2005;105:67–76.
20. Barrington JW, Arunkalaivanan AS, Abdel-Fattah M. Comparison between the levonorgestrel intrauterine system (LNG-IUS) and thermal balloon ablation in the treatment of menorrhagia. *Eur J Obstet Gynecol Reprod Biol* 2003;108:72–4.
  21. Grigorieva V, Chen-Mok M, Tarasova M, Mikhailov A. Use of a levonorgestrel-releasing intrauterine system to treat bleeding related to uterine leiomyomas. *Fertil Steril* 2003;79:1194–8.
  22. Sivin I, Stern J. Health during prolonged use of levonorgestrel 20 micrograms/d and the copper TCu 380Ag intrauterine contraceptive devices: a multicenter study. International Committee for Contraception Research (ICCR). *Fertil Steril* 1994;61:70–7.
  23. Soysal S, Soysal ME. The efficacy of levonorgestrel-releasing intrauterine device in selected cases of myoma-related menorrhagia: a prospective controlled trial. *Gynecol Obstet Invest* 2005;59:29–35.
  24. Rosa e Silva JC, de Sa Rosa e Silva AC, dos Reis FJ, et al. Use of a levonorgestrel-releasing intrauterine device for the symptomatic treatment of uterine myomas. *J Reprod Med* 2005;50:613–7.
  25. Soysal ME, Soysal SK, Vicdan K. Thermal balloon ablation in myoma-induced menorrhagia under local anesthesia. *Gynecol Obstet Invest* 2001;51:128–33.
  26. Glasser MH, Zimmerman JD. The HydroThermAblator system for management of menorrhagia in women with submucous myomas: 12- to 20-month follow-up. *J Am Assoc Gynecol Laparosc* 2003;10:521–7.
  27. Sabbah R. Preliminary clinical results with the use of the NovaSure system in patients with submucous fibroids. *J Am Gynecol Laparosc* 2003;10:S31.
  28. Anderson TL, Laberge P, Cooper K, Love B. Microwave endometrial ablation: two year results of a randomized multicenter evaluation. *J Am Assoc Gynecol Laparosc* 2003;10:S4.
  29. Goldberg J, McCrosson S, Kaulback KR. Fibroid degeneration following microwave endometrial ablation. *Obstet Gynecol* 2005;106(5 Pt 2):1176–8.
  30. Lee CH, Chang CC, Kuo YT. Color Doppler evaluation of blood flow changes in leiomyomas after uterine artery ligation. *Int J Gynaecol Obstet* 2005;90:118–22.
  31. Hald K, Langebrette A, Klow N, et al. Laparoscopic occlusion of uterine vessels for the treatment of symptomatic fibroids: initial experience and comparison to uterine artery embolization. *Am J Obstet Gynecol* 2004;190:37–43.
  32. Chen YJ, Wang PH, Yuan CC, et al. Pregnancy following treatment of symptomatic myomas with laparoscopic bipolar coagulation of uterine vessels. *Hum Reprod* 2003;18:1077–81.
  33. Holub Z, Eim J, Jabor A, et al. Complications and myoma recurrence after laparoscopic uterine artery occlusion for symptomatic myomas. *J Obstet Gynaecol Res* 2006;32:55–62.
  34. Magnetic resonance-guided focused ultrasound therapy for symptomatic uterine fibroids. *Technol Eval Cent Asses Program Exec Summ* 2005;20:1–3.
  35. Cowan BD, Sewell PE, Howard JC, et al. Interventional magnetic resonance imaging cryotherapy of uterine fibroid tumors: preliminary observation. *Am J Obstet Gynecol* 2002;186:1183–87.
  36. Tempany CM, Stewart EA, McDannold N, et al. MR imaging-guided focused ultrasound surgery of uterine leiomyomas: a feasibility study. *Radiology* 2003;226:897–905.
  37. Stewart EA, Gedroyc WM, Tempany CM, et al. Focused ultrasound treatment of uterine fibroid tumors: safety and feasibility of a noninvasive thermoablative technique. *Am J Obstet Gynecol* 2003;189:48–54.
  38. Fennessy FM, Tempany CM. MRI-guided focused ultrasound surgery of uterine leiomyomas. *Acad Radiol* 2005;12:1158–66.
  39. Hindley J, Gedroyc WM, Regan L, et al. MRI guidance of focused ultrasound therapy of uterine fibroids: early results [published erratum appears in *AJR Am J Roentgenol* 2005;184:348]. *AJR Am J Roentgenol* 2004;183:1713–9.
  40. Stewart EA, Rabinovici J, Tempany CMC, et al. Clinical outcomes of focused ultrasound surgery for the treatment of uterine fibroids [published erratum appears in *Fertil Steril* 2006;85:1072]. *Fertil Steril* 2006;85:22–9.
  41. Goldfarb HA. Bipolar laparoscopic needles for myoma coagulation. *J Am Assoc Gynecol Laparosc* 1995;2:175–9.
  42. Zreik TG, Rutherford TJ, Palter SF, et al. Cryomyolysis, a new procedure for the conservative treatment of uterine fibroids. *J Am Assoc Gynecol Laparosc* 1998;5:33–8.
  43. Vilos GA, Vilos EC, Romano W, Abu-Rafea B. Temporary uterine artery occlusion for treatment of menorrhagia and uterine fibroids using an incisionless Doppler-guided transvaginal clamp: case report. *Human Reprod* 2006;21:269–71.



**CME EVALUATION: Minimally Invasive Treatment Options for Uterine Fibroids**

**DIRECTIONS:** Each of the questions below is followed by several possible answers. Select the ONE lettered answer that is BEST in each case and circle the corresponding letter on the answer sheet.

1. A 25-year-old woman is referred for evaluation of abdominal pain and diarrhea. She has had similar symptoms on and off for the past 7 years. The pain is relieved following bowel movements. There is no bleeding or weight loss. Laboratory tests are normal. On physical examination, there is mild tenderness in the left lower quadrant. Which of the following statements regarding additional workup in this case is true?
  - (A) Any patient with abdominal pain and irregular bowel movements should have a colonoscopy to the cecum
  - (B) Abdominal ultrasound is likely to provide an explanation for the pain and tenderness
  - (C) At age 25, in the absence of "red flags," colonoscopy to the cecum is not indicated
  - (D) Rare cases of diarrhea such as neuroendocrine tumors must be ruled out
2. A 30-year-old man with abdominal pain and constipation has undergone a comprehensive diagnostic workup by his family physician. The results of the tests are negative and the patient is diagnosed as suffering from IBS. Which of the following statements concerning treatment for IBS is TRUE?
  - (A) The first physician-patient encounter has no special therapeutic significance
  - (B) IBS can be cured if the appropriate treatment is offered to the patient
  - (C) The effectiveness of cognitive-behavioral therapy has been disproved in clinical trials
  - (D) Hypnosis has been shown in clinical trials to be effective in IBS
3. Visceral hypersensitivity is
  - (A) A phenomenon that is associated with brain-gut dysregulation
  - (B) A theory that supports the psychological etiology of IBS
  - (C) The missing link that connects highly sensitive personality types to IBS
  - (D) A pathognomic marker for IBS
4. Which of the following statements concerning IBS and fibromyalgia is TRUE?
  - (A) Both may be described as a state of hypervigilance to peripheral pain stimuli (visceral or somatic)
  - (B) Both are characterized by male predominance
  - (C) Neither takes a significant toll in terms of work absenteeism and economic burden on society
  - (D) No good epidemiological surveys of these disorders have been conducted to date
5. Which of the following statements about patients with IBS and another functional disorder as compared with those with IBS only is TRUE?
  - (A) They have less sleep impairment
  - (B) They are more likely to suffer from a form of somatization disorder
  - (C) Their quality of life is better
  - (D) They are less likely to be chronic health care seekers



EVALUATION FORM: Minimally Invasive Treatment Options for Uterine Fibroids

Participants may earn 1 credit by reading the article named above and correctly answering at least 70% of the accompanying test questions. A certificate of credit and the correct answers will be mailed within 6 weeks of receipt of this page to those who successfully complete the test.

Circle your answer to the CME questions below:

- 1. A B C D
2. A B C D
3. A B C D
4. A B C D
5. A B C D

Please answer the following questions:

- 1. How would you rate this educational activity overall?
2. This article was fair, balanced, free of commercial bias, and fully supported by scientific evidence.
3. Please rate the clarity of the material presented in the article.
4. How helpful to your clinical practice was this article?
5. What changes will you make in your practice as a result of reading this article?

Blank lines for writing answers to question 5.

Blank lines for writing answers to question 6.

Release date: 15 September 2006
Expiration date: 30 September 2007

Please print clearly:

Name:
MD/DO/Other:
Address:
City:
State: Zip:
Phone:
Fax:
E-mail:

Are you a health care professional licensed to practice in the US/ Canada who can use Category 1 AMA PRA CME credit to fulfill educational requirements? Yes No

Physicians are required to report the actual amount of time spent on the activity, up to the maximum designated 1 hour. The actual time spent reading this article and completing the test was

Please mail or fax this sheet to:

Wayne State University, Division of CME
101 E. Alexandrine, Lower Level
Detroit, MI 48201
FAX: 313-577-7554

This activity has been planned and implemented in accordance with the Essential Areas and Policies of the Accreditation Council for Continuing Medical Education (ACCME) through the joint sponsorship of Wayne State University School of Medicine and the Journal of Clinical Outcomes Management. Wayne State University School of Medicine is accredited by the ACCME to provide continuing medical education for physicians. Wayne State University School of Medicine designates this educational activity for a maximum of 1 AMA PRA Category 1 credits. Physicians should only claim credit commensurate with the extent of their participation in the activity.